

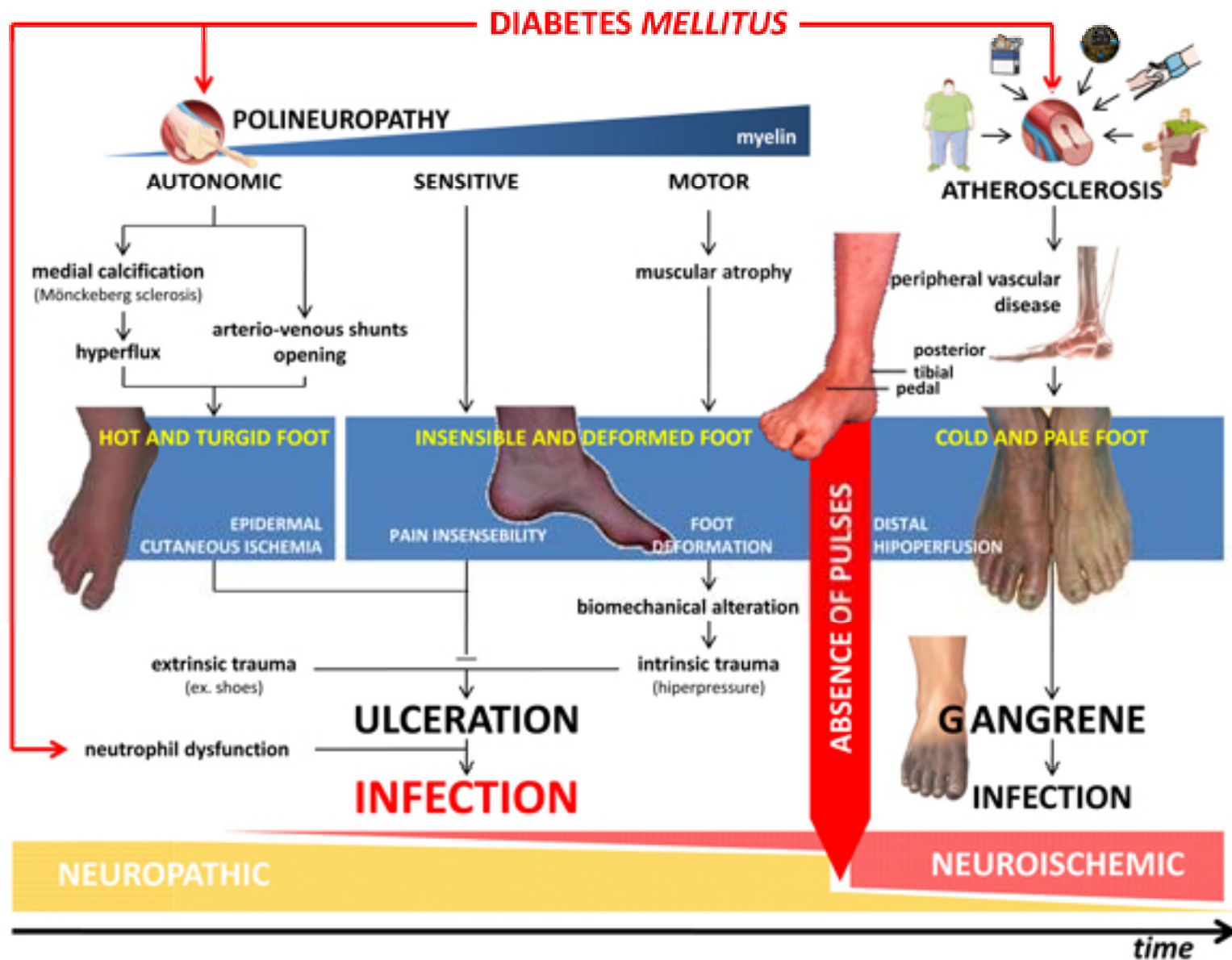
IL PIEDE DEL DIABETICO

Angela Groger

Chirurgo Cardio-Vascolare

Trauma Center

A O R N Cardarelli



Classification of diabetic foot ulcer

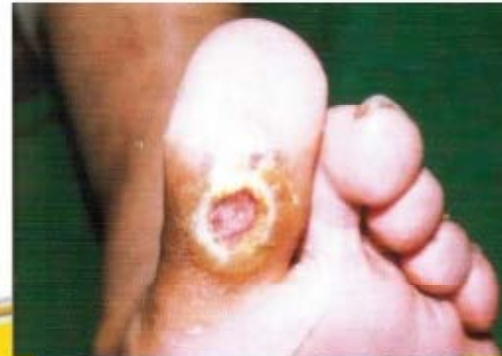Wagner Grading System

- Grade 0 skin intact but "foot at risk"
- Grade 1: Superficial Diabetic Ulcer & localised
- Grade 2: Deep ulcer & extension
 - Involves ligament, tendon, joint capsule or fascia
 - No abscess or [Osteomyelitis](#)
- Grade 3: Deep ulcer with abscess or [Osteomyelitis](#)
- Grade 4: Gangrene to portion of forefoot
- Grade 5: Extensive gangrene of entire foot

Lesione da neuropatia

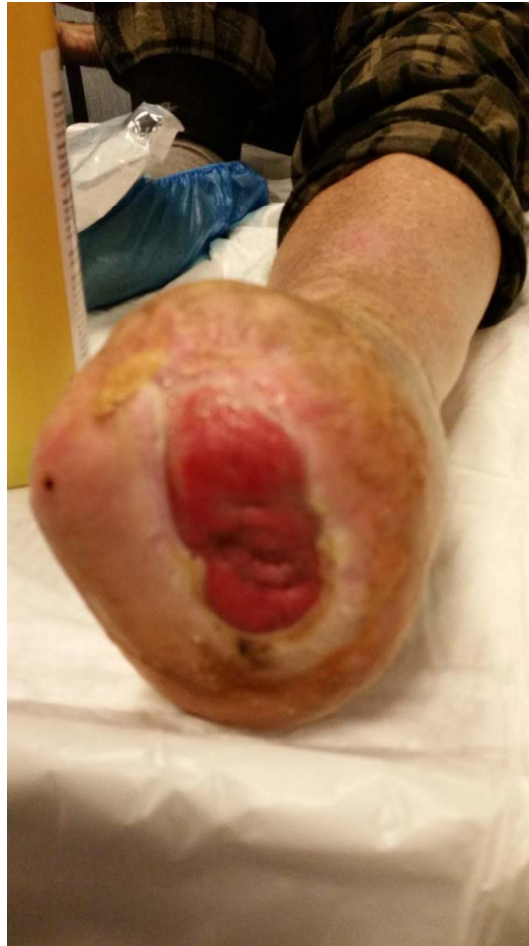The neuropathic foot

- Ulcer often preceded by callus formation.
- Ulcers can be secondarily infected.
- Quickly lead to cellulitis, abscess formation, and osteomyelitis.
- Sepsis may complicate, resulting in gangrene.

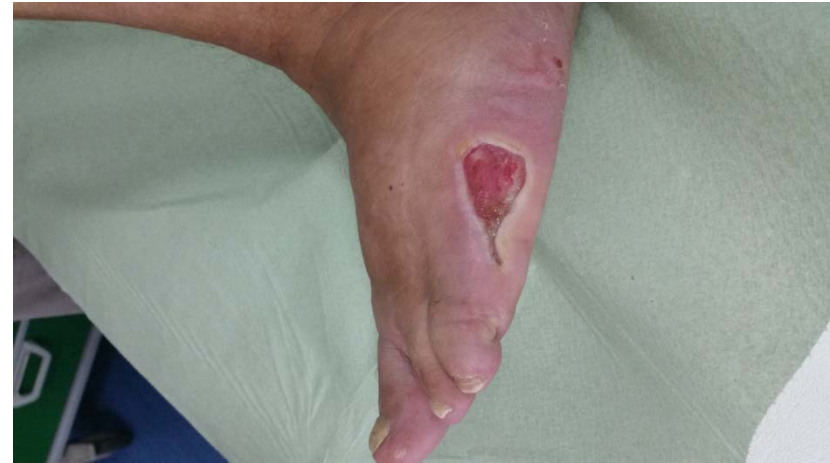
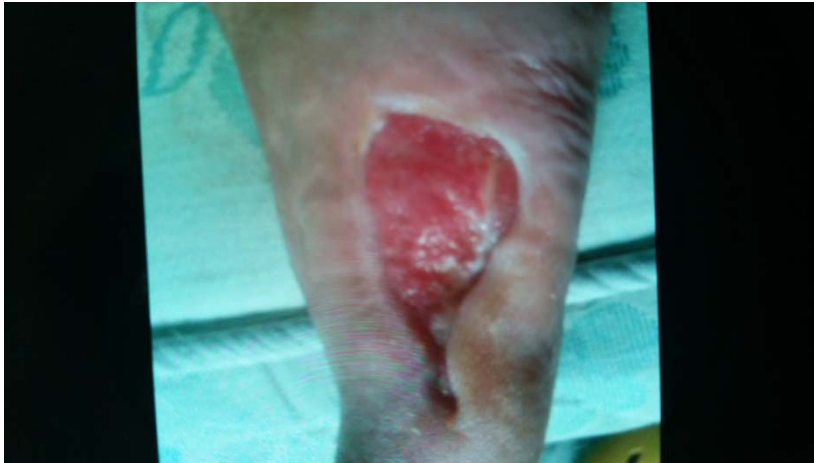
Neuropathic ulcer

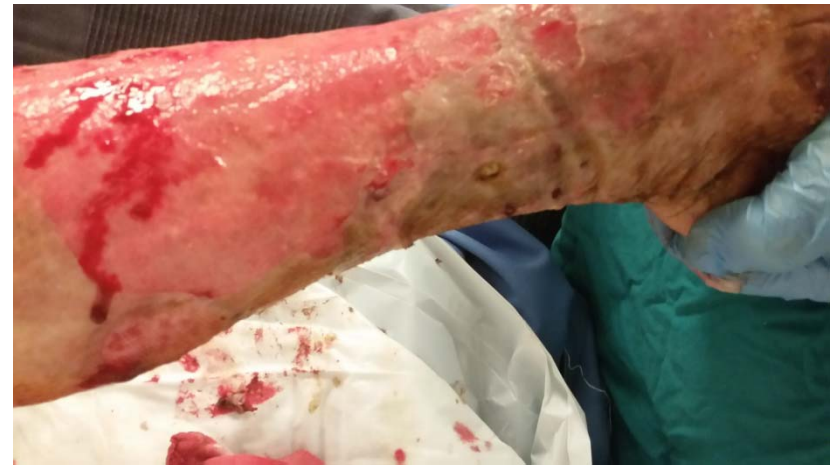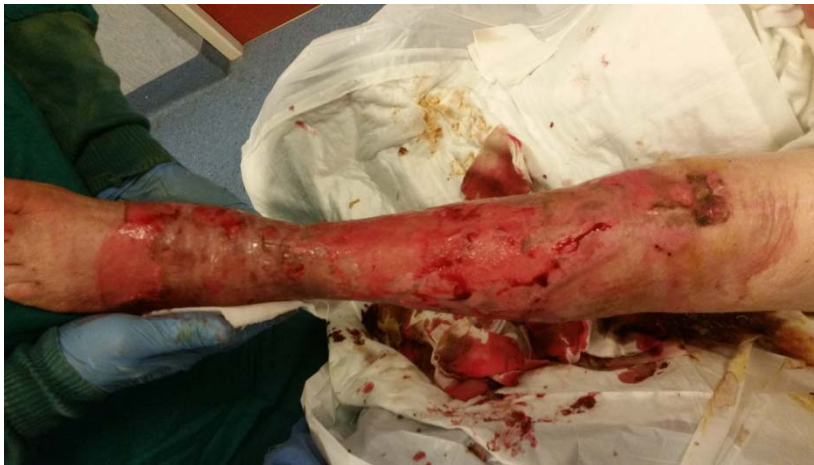Primary Wound Dressing



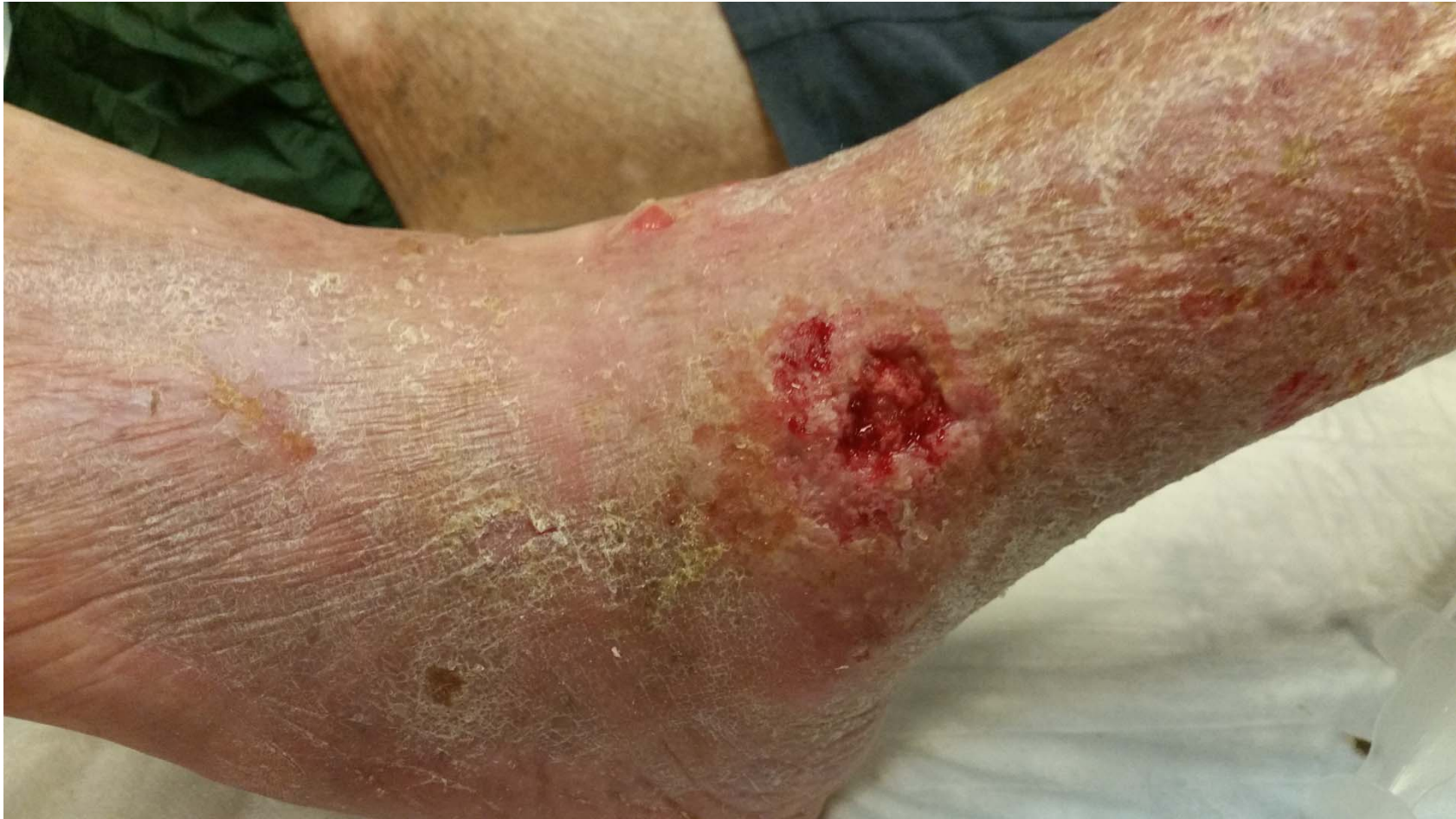Primary Wound Dressing



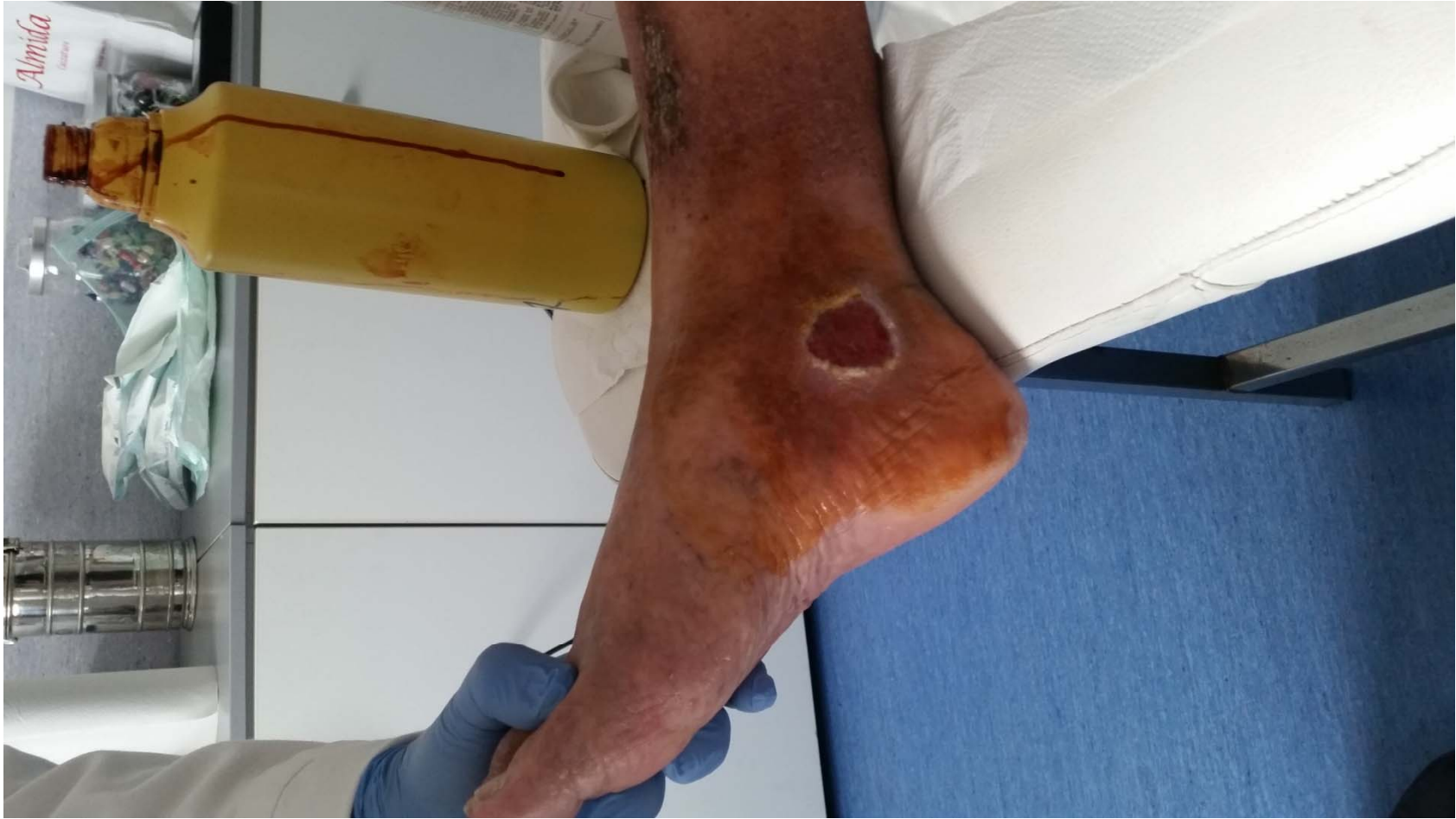Primary Wound Dressing



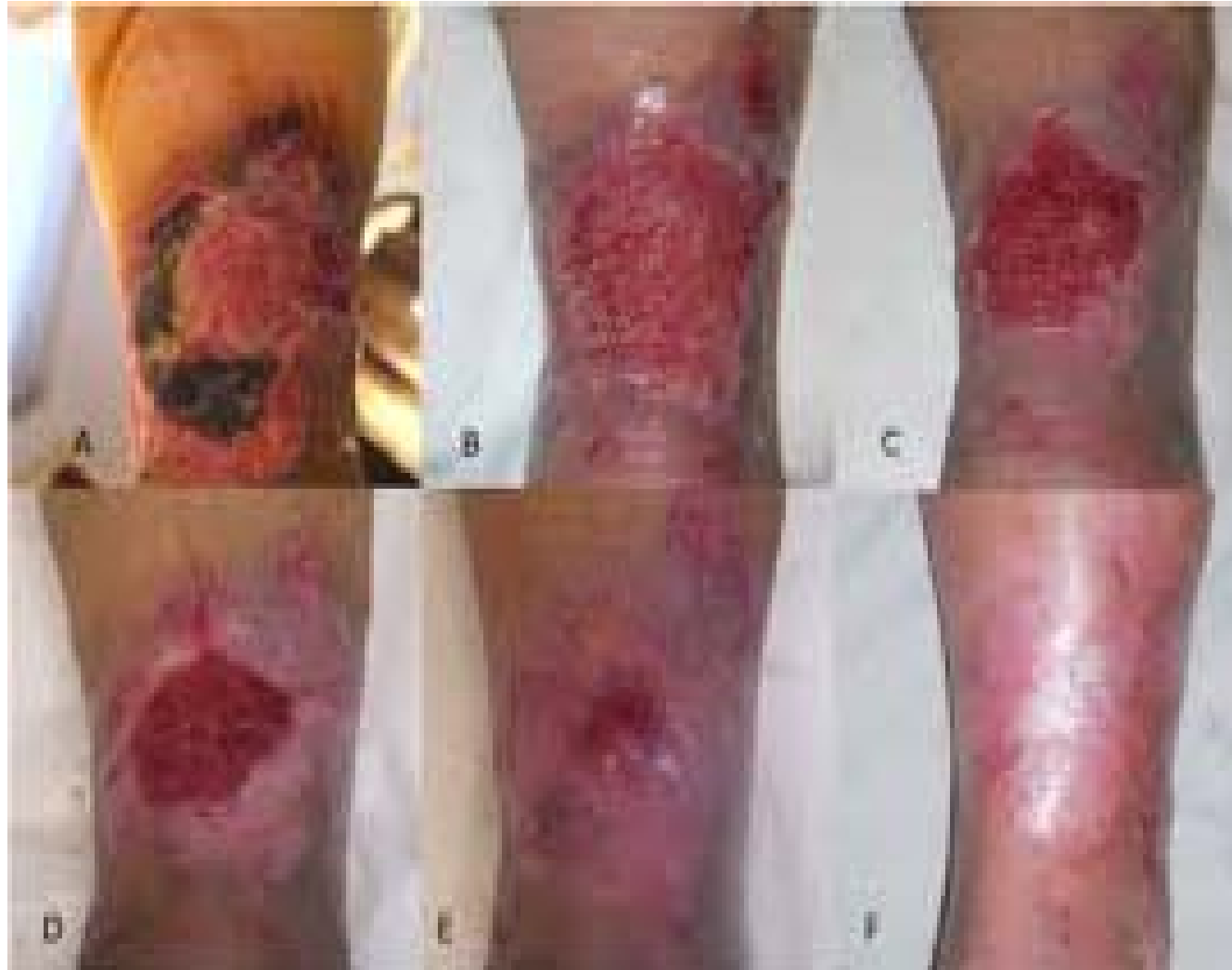Primary Wound Dressing



Primary Wound Dressing



Primary Wound Dressing





Grazie